

Liver Biopsy and Serious Complications : How to Prevent ?

Treeprasertsuk S

ABSTRACT

Liver biopsy still plays an important role for evaluation of the etiology and assesses severity of liver diseases for 116 years. However, the complication of this procedure still remains the problems in medical practice. Therefore, this review aims to update and focus to the step of care to prevent or reduce serious complications of liver biopsy. Selecting the proper patients with reasonable indications and avoid liver biopsy in the contraindicated patients. The patient should be informed for indication, contraindications, alternatives, risks and benefits associated with liver biopsy. Liver biopsy procedure for selected proper patients can be performed as an outpatient basis. Finally, the early recognition for these complications was the highly suspicion for the clinical symptoms and signs of complications and must tell the patients about the onset of complications which usually occurred within 24 hours or delay bleeding can occurred within 7 days.

Key words : liver biopsy, complication

[Thai J Gastroenterol 2008; 9(1): 35-42.]

Paul Ehrlich was the first physician who performed a percutaneous liver biopsy in Germany in 1883 (Figure 1) and Menghini developed a new aspiration technique since late 1950, which introduced the easier method for liver biopsy procedure⁽¹⁻³⁾. However, the complication of this procedure still remains the problems in medical practice. Therefore, this review aims to update and focus to the step of care to prevent or reduce serious complications of liver biopsy.

Role of liver biopsy for diagnosis liver problems: risks and benefits

The efficacy of serum aminotransferase elevations and ultrasonography for assessment the liver's inflammation activity and degree of fibrosis are still limit.




Figure 1 *Paul Ehrlich: German physician, bacteriologist, and chemist (1854-1915) : the first physician who performed liver biopsy since 1883 and he was awarded the Nobel Prize for physiology or medicine for his work on immunity and serum therapy in 1908.*

Liver biopsy is helpful and also indicated for diagnosis of several liver problems such as autoimmune hepatitis, primary biliary cirrhosis and other unknown causes of prolonged elevation liver enzymes. However, in some diseases with benign causes, it's still controversy to perform liver biopsy such as fatty liver disease and chronic hepatitis C, genotype 3. Role of liver biopsy post liver transplantation is increasing, and policies on histological evaluation vary between centers. Some centers perform routine liver biopsies on day 7th post-transplant to assess acute rejection.⁽⁴⁾ Liver biopsy is also useful for the diagnosis of opportunistic infection in immunocompromised hosts such as cytomegalovirus infection. There are 2 types of needle biopsy: cutting needle (Tru-cut) and aspiration needle (Menghini) (Figure 2-4). The cutting needle is supe-

Liver Biopsy and Serious Complications : How to Prevent ?

rior in the aspect of less fragmented specimen while its weak point is the association with higher serious complication rate such as hemorrhagic complications, pneumothorax, and biliary peritonitis.^(5,6)

Indication for liver biopsy⁽¹⁾

1. Evaluation of abnormal liver function tests which can not explained by blood tests
2. Confirmation of diagnosis and assess severity of disease such as autoimmune hepatitis, chronic hepatitis C genotype 1
3. Suspected liver tumor and / or differentiate between benign and malignant liver mass
4. Diagnosis the cause of cholestatic liver disease such as PBC, drugs induced liver injury (DILI)
5. Evaluation of infiltrative or granulomatous

Hepafix® Presentations

Gauge/outer Diameter mm x length mm	Code No. (REF)	Sales unit/ Pcs.
G18/1.2 x 88	4801121	25
G17/1.4 x 88	4801148	25
G16/1.6 x 88	4801164	25
G15/1.8 x 88	4801180	25

All materials used are free from PVC and latex.

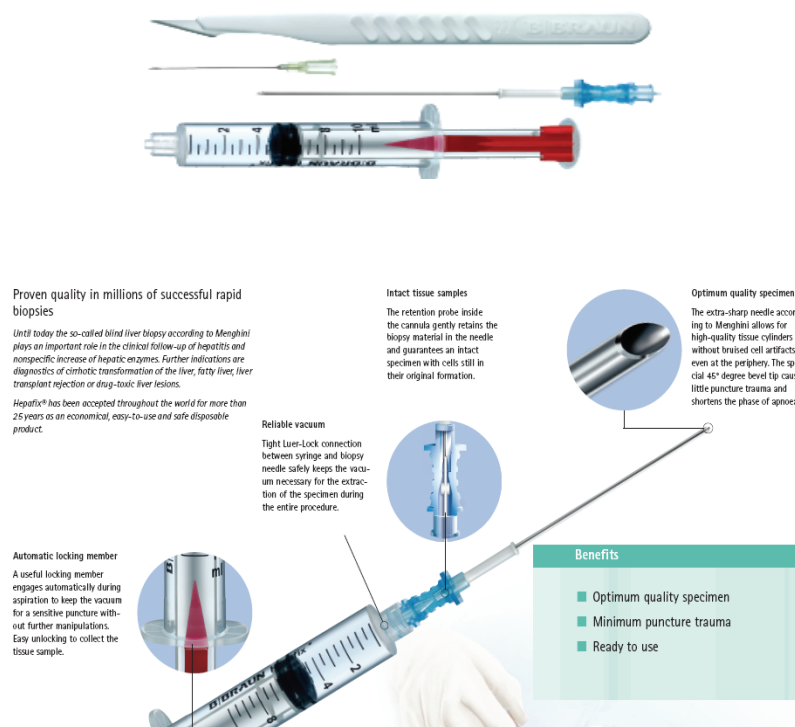


Figure 2-3 Aspiration needle for liver biopsy (Menghini).

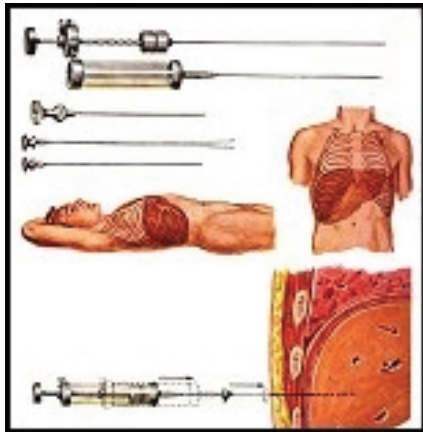


Figure 4 Cutting needle for liver biopsy (Tru-cut).

Table 1 Contraindication for liver biopsy

Absolute	Relative
Coagulopathy	Ascites
Prothrombin time ≥ 4 seconds over control (INR > 1.6)	Infections in right pleural cavity
Platelets $< 60,000/\text{mm}^3$	Infection below right diaphragm
Prolonged bleeding time	
Unavailability of blood transfusion support	
Suspected Echinococcal disease	
Presumed hemangioma	
Uncooperative patient	

disease especially in Immunocompromised hosts such as AIDS with prolonged fever

6. Following a case of liver transplantation to evaluate the occurrence of graft rejection

Contraindication for liver biopsy (Table 1)

The procedure should be performed post getting informed consent with adequate given information to the patients. This step of approach composes of:

- Patients position is in supine with extend their right arm. (Figure 5)
- Liver span is confirmed by percussion and exam with ultrasonography of liver
- Medical sedation should be given to less pain and anxiety
- Prepare the set of needle biopsy, normal saline, xylocaine and antiseptic. (Figure 6)
- If suspect for diffuse liver disease such as chronic viral hepatitis, the proper puncture site is ap-

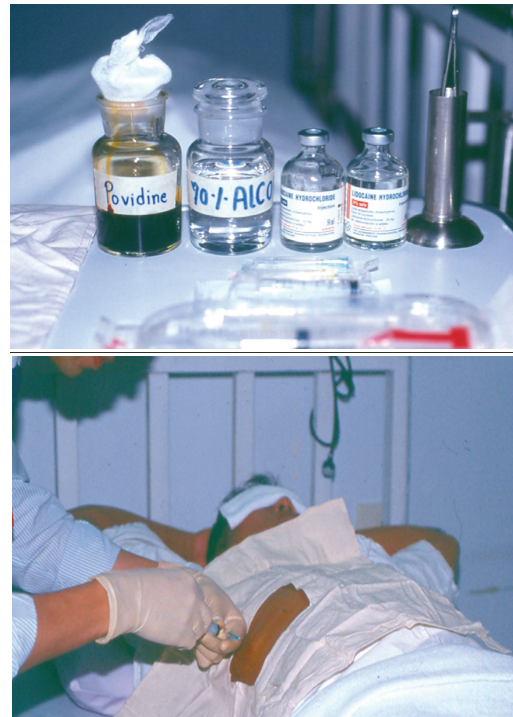

Figure 5-6 Prepare the set of needle biopsy, normal saline, xylocaine, antiseptic and patients' position.

proximately in the 7th - 9th intercostal space cross with the mid- to anterior axillary line.

- Prep the puncture site with antiseptic such as betadine and dry.
- Local infiltrate with xylocaine extend to the liver capsule.
- The needle should be punctured between intercostal space at the marked site and point to the xiphoid process.
- After getting through the local tissue, then flush the syringe with 1-2 ml. of normal saline.
- Ask the patients to hold their breath in expiration phase for 10 seconds.
- Retract the syringe with needle biopsy to create negative pressure and pass quickly into liver and withdrawn.
- Liver specimen should be placed on a small wax-paper before transferring to formalin-container.
- Keep the patients lie on their right lateral decubitus position for at least 1 hour and keep bed rest for 4-6 hours depend on hospital facility and policy.

Alternatives for percutaneous liver biopsy

1. Transjugular liver biopsy (TJLB) In case of high risk patients who need liver biopsy for clinical management, an alternative such as a may be a good

choice. However, the cost of TJLB is still expensive and it needs special technical support and experienced clinicians. Transjugular liver biopsy (TJLB) is also considered an inferior biopsy for the aspect of tissue adequacy. Minor and major complication rates were 6.5% and 0.56%, respectively, and increased in children, but not with additional passes. In adults, mortality was 0.09% (hemorrhage 0.06%; ventricular arrhythmia 0.03%).⁽⁷⁾ Bleeding is still the major complication in general patients.⁽⁸⁻¹⁰⁾ By histologic point of view, an adequate liver biopsy specimen were also an important factor. Recently the definition of adequate liver specimen from biopsy is 20-25 mm in length and/or containing more than 11 complete portal tracts.¹ The independent variables which associated with an adequate histological diagnosis were the longer liver specimen length ($p < 0.001$) and the lesser number of fragmented liver tissue < 2 ($p < 0.001$). Adequacy of liver specimen may related to the technique of liver biopsy used. There was a study compared percutaneous liver biopsy (PLB) and transjugular liver biopsy (TJLB) techniques and showed the different diagnostic yield. Using PLB techniques showed the mean size \pm SD of liver specimens of 17.7 ± 5.8 mm in length and the number of complete portal tracts was 7.5 ± 3.4 . While using TJLB techniques, the mean length \pm SD of liver biopsy was 13.5 ± 4.5 mm and the number of complete portal tracts was 6.8 ± 2.3 .⁽¹¹⁾ Therefore, the clinicians have to discuss with their patients for the risks and benefits from these different techniques and the limitation of histopathologic interpretation from sampling errors and the chance of inadequate liver specimens. Selection the proper needle type in TJLB is also important. The cutting needles compose of the cutting type and the aspiration needles. Although there were conflicting data related to their tissue diagnostic yield, safety, and accuracy of both needles for diagnosing liver diseases, however the type of needle preference is based on its availability, personal experience, and the clinical situation. Up to present time, there is a new automated device with a Tru-Cut-type needle for TJLB which is designed to compared with the traditional needle in terms of efficacy and safety. However, there was no significant differences were observed in complication rates between both devices (7.14% vs. 10.7%; $p = \text{NS}$). However, this new device showed a higher diagnostic yield in the aspect of adequate obtaining of liver specimens. It can get 15 complete portal tracts and/or 25 mm in the length of liver speci-

mens which used at least three cores at each TJLB, independent of the presence of cirrhosis.^(12,13)

2. Mini-laparoscopic procedure for liver biopsy This is a new technique to reduce the severe complications of percutaneous liver biopsy. It showed lower complication rate found only in 0.2% compared to PLB which showed serious complications rate of 1.0-4.0% ($p = 0.025$)⁽¹⁴⁾, however it costs a much higher expenditure and it is inconvenient for general use.

Major complications from liver biopsy

In the aspects of risks, indicated patients for liver biopsy can be classified into the low risk and the high risk patients which have the different rate of complications. The complication severity can classify into 2 major groups: the first one is mild complications which define as the symptoms and signs that need hospitalization for few days. For example, in case of mild bleeding complication, it means a reduction of hematocrit value but there is no need to transfuse blood. Secondly, the major or severe complications include the life threatening condition or bleeding complication which necessitated transfusion or surgery or resulted in death. Moreover, these informed data related to complications rate in consent form should be based on the true prevalence or incidence in their hospital or their countries. The major complications include the following:

1. Bleeding complications In Thailand, there were 5 studies related to complications occurred from liver biopsy during 1952-2003 and their number of cases varied from 40 to 484 percutaneous liver biopsies which showed the total complication rate ranged from 4.0-6.4%. Major bleeding and / or bile peritonitis was found in about 2.0-4.5% and death rate was 1.6% as shown in Table 1.⁽¹⁵⁻¹⁹⁾ This major complication seemed to be higher than in other centers such as in Mayo Clinic which showed the mortality from fatal hemorrhage after percutaneous liver biopsy in about 0.11%.⁽²⁰⁾ And the mortality rate in United Kingdom district general hospitals was 0.13-0.33%.⁽²¹⁾ However, the trend of major complication was declined due to the better step of care and more experienced hepatologists. The important risk factors correlated with bleeding risks and deaths were a low platelet count ($\leq 70 \times 10^9 / \text{L}$), a prolonged prothrombin time (> 3 seconds over control), or a prolonged activated partial thromboplastin time (> 10 seconds over control).⁽¹⁵⁻¹⁷⁾ Moreover, the number of more than 3 times of liver

biopsy in a patient was correlated with an increased incidence of bleeding complications.⁽²²⁾

To avoid these complications, ultrasound guidance technique for liver biopsy was introduced since 1996 and confirmed the benefit of decreasing the major complications rate, and also caused significantly less biopsy pain.⁽²³⁾ There was study related to the cost-effectiveness of ultrasound-guided and showed that if the marginal effectiveness expressed as the number of major complications avoided was 1.2/100 liver biopsies, this technique was cost-effective and confirmed even in children patients in 2003.^(23,24)

The recovery time post liver biopsy is also the issue discussed for the proper management. There was a study done in Florida, USA between February 1995 and June 2004 showed the reduction of recovery time from 6 hours before 1997 to 1 hour in 2002 with complication rate of 1.7%. The majority of these complications found within 1 hour of the observation period or within 1 day after discharge therefore outpatient liver biopsy can be safely done in most cases.⁽²⁵⁻²⁷⁾ Delayed bleeding occurs much less frequently but it has a higher mortality as shown in a case report of delayed bleeding intra-abdomen at 5 days post liver biopsy that caused by a pseudoaneurysm of the hepatic artery.⁽²⁸⁾

Another rare complication related to liver biopsy and occurred lately was hemobilia which found 6 days post liver biopsy. The incidence of hemobilia following percutaneous liver biopsy ranges between 0.05-1%.⁽²⁹⁾ Patients present with biliary pain, jaundice and

melenia. The serious biopsy-related bleeding events from other center such as Germany was quite similar to the data from USA in the same period, which found in about 1.6%, while the minor bleeding complication rate was 2.7%.⁽³⁰⁾ From this study, they found the risk factors to predict the high risk group of bleeding complication and found in cases that suspected for mycobacterial infection (OR 24.0), pre-biopsy prophylactic platelet transfusion (OR 9.9), acute liver failure (OR 9.1), heparin was given on the day of liver biopsy performed (OR 8.7), advanced liver cirrhosis (OR 5.1), treatment with corticosteroids (OR 3.5) or metimazole (OR 2.8) and leukemia or lymphoma (OR 2.8) were the high risk patients.^{(p ≤ 0.05).}⁽³⁰⁾ Delayed bleeding (> 24 h after biopsy) was identified in 70% of the bleeding events in this study.⁽³⁰⁾ Treatment with arterial embolization may rarely be required.

2. Bile peritonitis The clinical diagnosis for this complication is not difficult because the clinician must get aspiration of bile during liver biopsy. This was found in 0.5-0.9% of cases despite the standard selection of indicated patients and exclude all of the contraindications.⁽³¹⁾ However, the ultrasonography guided percutaneous liver biopsy may be the important tool to reduce the chance of puncture of the gallbladder. Most of these patients had acute onset of severe abdominal pain from bile peritonitis.⁽³²⁾ The management is to stabilized hemodynamic with adequate analgesic treatment and antibiotics. In some reports, the conservative treatment may successfully

Table 2 Five studies related to complications occurred from liver biopsy during 1952-2003.

	Viranuvatti V. 1952	Fuangpet Kiatisevi 1984	Pongchairerks P. 1993	Thampanit- chawong P. 1999	Treeprasertsuk S. 2003
Number of patients	40	100	97	484	52
Needle type	-	Vim-Silverman	Tru-cut	-	Menghini (Hepafix)
Ultrasound-guided	no	yes	yes	-	yes
Overall complication	6%	0	5.1%	6.4%	4%
- Pain (severe)	2	-	-	-	-
- Bile peritonitis	1	-	-	-	2%
- Fever	-	-	1%	-	-
- Transient - Hypotension	-	-	-	-	2%
- Bleeding	-	-	3%	4.5%	-
- Hemobilia	-	-	1%	-	-
- Mortality rate	0	0	0	1.6%	0

managed.⁽³³⁾ Laparoscopy to manage bile peritonitis after liver biopsy by suction and irrigation showed a better result than conventional laparotomy. Its advantages were lower intraoperative risk, shorter recovery time, and superior visualization of peritoneal contents.⁽³⁴⁾

3. Tumor seeding The prevalence rate of tumor seeding was 1-5% (median = 2.29%) of liver biopsy patients with the indication of suspicion of hepatocellular carcinoma (HCC) or other neoplasms or post radiofrequency ablation (RFA) of liver tumors.⁽³⁵⁾ It appears higher incidence with using diagnostic biopsy compared to therapeutic percutaneous procedures such as RFA.⁽³⁵⁾ The risk factors for tumor seeding included subcapsular lesion (OR = 11.57, $p = 0.007$), multiple treatment sessions (OR = 2.0, $p = 0.037$), and multiple electrode placements (OR = 1.4, $p = 0.006$).^(36,37) The seeding appeared in average 267 days after the biopsy (range, 116-619 days).⁽³⁸⁾ The diagnosis was confirmed by fine needle aspiration of the nodule or surgical specimen removal from needle tracts.⁽³⁹⁾ These implants were managed with wide surgical excision. Data from cases report showed that tumor seeding from HCC was controlled successful by resection (2 from 5 patients). This complication occurred lately but changed a potentially curative disease into an untreatable situation therefore some experts suggested to use of fine needle biopsy for HCC diagnosis instead of the standard size of needle.⁽⁴⁰⁾

4. Minor Pain Using ultrasound-guided percutaneous liver biopsy performed with IV sedative drugs such as Midazolam and/or fentanyl pre-medication is a suggested prevention.⁽⁴¹⁾

Frequent ask questions and managements for reduction the major complications

1. Is routine ultrasonography necessary post-procedure? Using ultrasound scans to all patients after liver biopsy or fine-needle aspiration (FNA) for early detection for complications is an issue to reduce severity of complication but there was a study performed and showed complication rate 0.25% and this one patient was asymptomatic. Therefore, routine ultrasonography is not necessary after these techniques.⁽⁴²⁾

2. Is using CT guidance for liver biopsy proven for complication reduction? CT guidance was 1.89 times more expensive than sonographic guidance. Sensitivity analyses indicate that CT and sonographic

guidance costs would be equivalent if the success rate with sonographic guidance was 39.8%. However, the US guidance was success in average rate higher than 60% therefore US guidance for liver biopsies is more economical than CT guidance.⁽⁹⁾

3. Is videolaparoscopy helpful for a diagnostic and therapeutic procedure for complication?

The new management for serious complications from liver biopsy is using videolaparoscopy as a diagnostic and therapeutic procedure. Gama-Odrigues J and colleagues showed the good outcome of management for hemobilia and bile peritonitis in two patients.⁽⁴³⁾ Cholecystectomy and ligation of the right branch of the hepatic artery were the major procedures for treating complicated patient underwent videolaparoscopic technique. Its advantages included low morbidity rates, quick recovery, and good cosmetic result. This new technique should be considered to be an alternative management of serious percutaneous liver biopsy complications.

The step of care for liver biopsy-patients

In 1999, British Society of Gastroenterology (BSG), together with the Royal College of Physicians of London, set the standard guideline for methods of liver biopsy in adults and summarized as follows:⁽⁴⁴⁾

1. Selecting the proper patients with reasonable indications and avoid liver biopsy in the contraindicated patients.
2. All of the information related to liver biopsy procedure must present in informed consent and inform to the patients with verbal and/or brochures
3. Discontinue aspirin 1 week prior to the procedure. However, NSAIDs (Nonsteroidal anti-inflammatory drugs), Clopidogrel, Warfarin are also suggest to stopped 5-7 days prior to the liver biopsy date. And, there was an reported case of delayed bleeding (15 days) especially in the patient with an early reinstatement of warfarin treatment after percutaneous liver biopsy.⁽⁴⁵⁾
4. The patient may be asked to fast an overnight to empty stomach because the chance of sedative drugs preprocedure may cause aspiration during the procedure.
5. Prophylactic antibiotics should be given to patients with valvular heart disease or those at risk of bacteremia.⁽⁴⁴⁾
6. Liver biopsy procedure for selected proper patients can be performed as an outpatient basis, fol-

lowing the recommendations outlined by American College of Physician practice guideline and British Society of Gastroenterology.

7. The patient must be accompanied by a reliable person because sedation with midazolam usually used for reduction their anxiety.

8. The patient should be informed for indication, contraindications, alternatives, risks and benefits associated with liver biopsy.

9. Blood tests for safety evaluation including prothrombin time and complete blood count, including platelets and ultrasonography of the liver (within 4 weeks) are required preprocedure.

10. Ultrasound guidance technique for liver biopsy was suggested and confirmed the benefit of decreasing the major complications rate.

11. In case of liver biopsy performed as an out-patient basis, the patient should admit for clinical observation post-procedure for at least 6 hours. However, there are increasing data confirm the safety of observation post-procedure for only 1-2 hours.

12. The early recognition for these complications was the highly suspicion for the clinical symptoms and signs of complications and must tell the patients about the onset of complications which usually occurred within 24 hours or delay bleeding can occurred within 7 days.

REFERENCES

- Bravo AA SS, Chopra S. Liver biopsy. *N Engl J Med* 2001; 344:495-500.
- Menghini G. One-second needle biopsy of the liver. *Gastroenterology* 1958;35:190-9.
- Menghini G LG, Caraceni M. Some innovations in the technique of the one-second needle biopsy of the liver. *Am J Gastroenterol* 1975;64:175-80.
- Nakhleh RE SS, Bloomer J, *et al.* The pathology of liver allografts surviving longer than one year. *Hepatology* 1990;11: 465-70.
- Brown KE WK, Brunt EM. Liver biopsy: indications, technique, complications and interpretation. 2006. p. 101-21.
- Piccininio F SE, Pasquale G, *et al.* Complications following percutaneous liver biopsy. *J Hepatol* 1986;2:165-73.
- Kalambokis G, Manousou P, Vibhakorn S, *et al.* Transjugular liver biopsy—indications, adequacy, quality of specimens, and complications—a systematic review. *J Hepatol* 2007;47:284-94.
- Friedman S. Controversies in liver biopsy: who, where, when, how, why? *Curr Gastroenterol Rep* 2004;6:30-6.
- Kliwer MA, Sheafor DH, Paulson EK, *et al.* Percutaneous liver biopsy: a cost-benefit analysis comparing sonographic and CT guidance. *Am J Roentgenol* 1999;173:1199-202.
- Senzolo M, Burra P, Cholongitas E, *et al.* The transjugular route: the key hole to the liver world. *Dig Liver Dis* 2007;39: 105-16.
- Cholongitas E, Senzolo M, Standish R, *et al.* A systematic review of the quality of liver biopsy specimens. *Am J Clin Pathol* 2006;125:710-21.
- Banares R, Alonso S, Catalina MV, *et al.* Randomized controlled trial of aspiration needle versus automated biopsy device for transjugular liver biopsy. *J Vasc Interv Radiol* 2001; 12:583-7.
- Cholongitas E, Quaglia A, Samonakis D, *et al.* Transjugular liver biopsy in patients with diffuse liver disease: comparison of three cores with one or two cores for accurate histological interpretation. *Liver Int* 2007;27:646-53.
- Denzer U, Arnoldy A, Kanzler S, *et al.* Prospective randomized comparison of minilaparoscopy and percutaneous liver biopsy: diagnosis of cirrhosis and complications. *J Clin Gastroenterol* 2007;41:103-10.
- Thampanitchawong P, Piratvisuth T. Liver biopsy: complications and risk factors. *World J Gastroenterol* 1999;5:301-4.
- Pongchairerks P. Ultrasound-guided liver biopsy: accuracy, safety and sonographic findings. *J Med Assoc Thai* 1993;76: 597-600.
- Treeprasertsuk S. Complications of percutaneous liver biopsy by ultrasound-guided in chronic viral hepatitis. *Thai J Gastroenterol* 2003;3:96-9.
- Kiatsevi F. A new diagnosis of carcinoma of liver by liver biopsy under ultrasonic guidance, experienced with 100 patients. *Bull Dept Med Serv* 1984;9:629-36.
- Viranuvatti V. Liver biopsy from 48 biopsies in 40 cases. *J Med Assoc Thai* 1952;35:21-58.
- McGill DB RJ, Zinsmeister AR, *et al.* A 21-year experience with major haemorrhage after percutaneous liver biopsy. *Gastroenterology* 1990;99:1396-400.
- Gilmore IT BA, Murray-Lyon IM, *et al.* Indications, methods, and outcomes of percutaneous liver biopsy in England and Wales: an audit by the British Society of Gastroenterology and the Royal College of Physicians of London. *Gut* 1995; 36:437-41.
- Maharaj BI. Complications associated with percutaneous needle biopsy of the liver when one, two, or three specimens are taken. *Postgrad Med J* 1992;68:964-7.
- Nobili VCD, Sartorelli MR, Natali G, *et al.* Blind and ultrasound-guided percutaneous liver biopsy in children. *Pediatr Radiol* 2003;33:772-5.
- Pasha T, Gabriel S, Therneau T, *et al.* Cost-effectiveness of ultrasound-guided liver biopsy. *Hepatology* 1998;27:1220-6.
- Firpi RJ S-PC, Abdelmalek MF, Morelli G, *et al.* Short recovery time after percutaneous liver biopsy: should we change our current practices? *Clin Gastroenterol Hepatol* 2005;3: 926-9.
- Pawa S, Ehrinpreis M, Mutchnick M, *et al.* Percutaneous liver biopsy is safe in chronic hepatitis C patients with end-stage renal disease. *Clin Gastroenterol Hepatol* 2007;5:1316-20.

27. Rossi P, Sileri P, Gentileschi P, *et al.* Percutaneous liver biopsy using an ultrasound-guided subcostal route. *Dig Dis Sci* 2001;46:128-32.
28. Ahmed A, Samuels SL, Keeffe EB, *et al.* Delayed fatal hemorrhage from pseudoaneurysm of the hepatic artery after percutaneous liver biopsy. *Am J Gastroenterol* 2001;96:233-7.
29. Rossi P SP, Gentileschi P, Sica GS, *et al.* Delayed symptomatic hemobilia after ultrasound-guided liver biopsy: a case report. *Hepatogastroenterology* 2002;49:1659-62.
30. Terjung B, Lemnitzer I, Dumoulin FL, *et al.* Bleeding complications after percutaneous liver biopsy. An analysis of risk factors. *Digestion* 2003;67:138-45.
31. Angelucci E BD, Lucarelli G, Baldassarri M, *et al.* Needle liver biopsy in thalassaemia: analyses of diagnostic accuracy and safety in 1184 consecutive biopsies. *Br J Haematol* 1995; 89:757-61.
32. Paymani M ZA, Campbell WL. Bile leakage as a complication of liver biopsy in liver transplants. *Abdom Imaging* 1993; 18:258-60.
33. Ruben RA CS. Bile peritonitis after liver biopsy: nonsurgical management of a patient with an acute abdomen: a case report with review of the literature. *Am J Gastroenterol* 1987; 82:265-8.
34. Bornstein SJ CD, Lusk LB. Laparoscopic management of bile peritonitis after liver biopsy. *Surg Laparosc Endosc* 1991; 1:200-1.
35. Stigliano R, Marelli L, Yu D, *et al.* Seeding following percutaneous diagnostic and therapeutic approaches for hepatocellular carcinoma. What is the risk and the outcome? Seeding risk for percutaneous approach of HCC. *Cancer Treat Rev* 2007;33:437-47.
36. Jaskolka JD, Asch MR, Kachura JR, *et al.* Needle tract seeding after radiofrequency ablation of hepatic tumors. *J Vasc Interv Radiol* 2005;16:485-91.
37. Kim SH, Lim HK, Lee WJ, *et al.* Needle-tract implantation in hepatocellular carcinoma: frequency and CT findings after biopsy with a 19.5-gauge automated biopsy gun. *Abdom Imaging* 2000;25:246-50.
38. Chang S, Kim SH, Lim HK, *et al.* Needle tract implantation after sonographically guided percutaneous biopsy of hepatocellular carcinoma: evaluation of doubling time, frequency, and features on CT. *AJR Am J Roentgenol* 2005;185:400-5.
39. de Sio I, Castellano L, Calandra M, *et al.* Subcutaneous needle-tract seeding after fine needle aspiration biopsy of pancreatic liver metastasis. *Eur J Ultrasound* 2002;15:65-8.
40. Liu YW, Chen CL, Chen YS, *et al.* Needle tract implantation of hepatocellular carcinoma after fine needle biopsy. *Dig Dis Sci* 2007;52:228-31.
41. Tan KT, Rajan DK, Kachura JR, *et al.* Pain after percutaneous liver biopsy for diffuse hepatic disease: a randomized trial comparing subcostal and intercostal approaches. *J Vasc Interv Radiol* 2005;16:1215-9.
42. Carrera Alonso E, Garcia Gonzalez M, Valer Lopez-Fando P, *et al.* A prospective study about the usefulness of ultrasonographic monitoring after invasive liver procedures—liver biopsy and fine-needle aspiration (FNA). *Rev Esp Enferm Dig* 2007;99:128-31.
43. Gama-Odrigues J, Bresciani C, Seid VE. Videolaparoscopic management of percutaneous liver biopsy complications. *Surg Laparosc Endosc Percutan Tech* 2001;11:134-8.
44. Grant A NJ. Guidelines on the use of liver biopsy in clinical practice. *Gut* 1999;445:IV1-IV11
45. Reichert CM WL, Klein HG. Delayed haemorrhage after percutaneous liver biopsy. *J Clin Gastroenterol* 1983;5:263-6.